

Use of 27-Gauge Vitrectomy for Diabetic TRD

A pilot survey demonstrated anatomic success and visual improvement.

BY YUSUKE OSHIMA, MD

In 2010, we reported preliminary results using a first-generation 27-gauge vitrectomy system.¹ Although at that time it was used only in highly selected cases, mainly of macular disease and simple vitreous hemorrhage, both the anatomic and visual results were promising. The most remarkable findings were that there was no need to transition to a larger gauge, no suturing was required, and no hypotony was observed in any of the study cases.

To explore the potential for further widespread use of this ultrasmall-gauge system, we have moved to the next stage. We recently confirmed the system's feasibility for treating more challenging conditions, such as advanced proliferative diabetic retinopathy (PDR). Current indications for pars plana vitrectomy in patients with PDR include vitreous hemorrhage, tractional retinal detachment (TRD), diabetic macular edema associated with posterior hyaloidal traction, and anterior segment neovascularization with media opacities. Of these, TRDs with prominent fibrovascular membranes are the most challenging situations.

At a Glance

- The 27-gauge vitreous cutter is the best device for membrane dissection in diabetic eyes because it can be easily inserted between membranes.
- An improved, high-speed 27-gauge vitrectomy system offers anatomic success in patients with diabetic TRD similar to that of 23- and 25-gauge systems.
- Surgical procedures are simplified and operating times are shortened with the 27-gauge system.

"With adoption of chandelier endoillumination and wideangle viewing systems, vitreous shaving with a recently improved high-speed 27-gauge vitreous cutter can be smoothly achieved... "

In combination with recent advances in vitrectomy technologies and pharmacologic agents, the use of small-gauge vitrectomy systems has made it possible to achieve anatomic stability and improvement of visual acuity in eyes with diabetic TRD.

In this article, we describe preliminary results using 27-gauge vitrectomy for treating these challenging situations.

BENEFITS OF SMALL GAUGES

With adoption of chandelier endoillumination and wideangle viewing systems, vitreous shaving with a recently improved high-speed 27-gauge vitreous cutter can be smoothly achieved without undue concern about fragility or cutting efficiency. Based on our previous experiences with 23- and 25-gauge systems, we knew that a smaller-gauge cutter would be more useful for membrane dissection in diabetic eyes.² The 27-gauge vitreous cutter is currently the best device for this indication because it can be easily inserted into the tiny spaces between membranes without the need for complex instruments or special techniques (Figure 1).

Substantial benefits have been reported with the use of small-gauge systems in previous literature. For diabetic

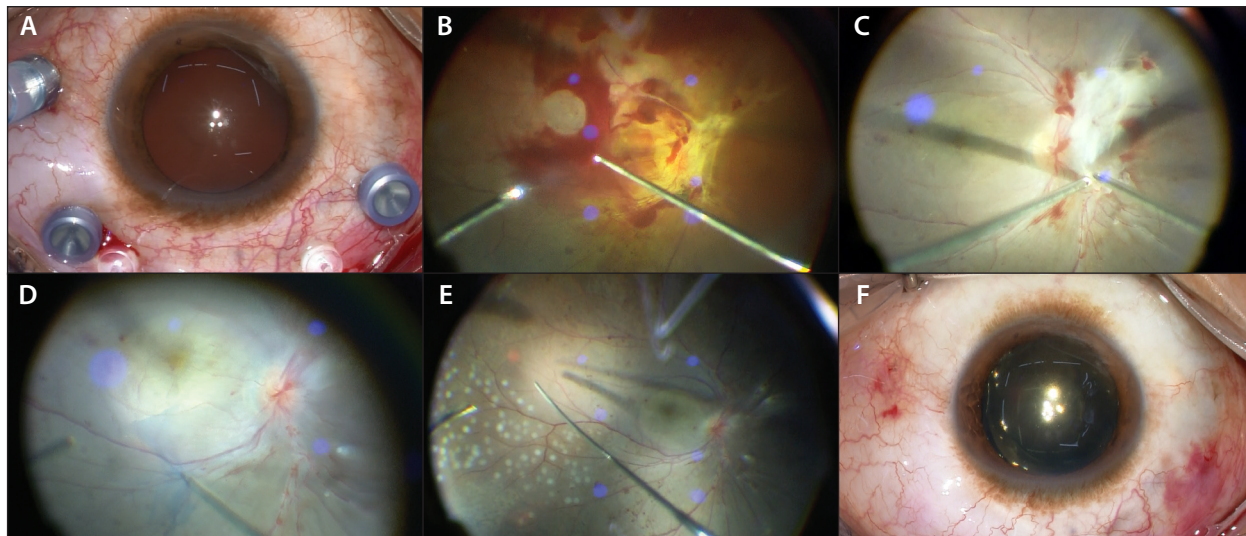


Figure 1. Microincision vitrectomy: 27-gauge three-port setting with 27-gauge twin-light chandelier endoillumination fibers (Twinlight chandelier illumination system; A); vitreous hemorrhage removal with 27-gauge twin-duty cycle (TDC) cutter (B); bimanual manipulation using TDC cutter with membrane forceps for membrane dissection (C); internal limiting membrane peeling with 27-gauge forceps (D); panretinal endophotocoagulation with a 27-gauge curved endolaser probe (E); external view of eye immediately after conclusion of 27-gauge diabetic vitrectomy (F).

patients, in addition to these reported benefits, it is important to ensure rigid wound construction to maintain intraocular pressure stability in order to prevent postoperative hypotony-related bleeding complications. Preservation of the conjunctiva is another important goal. For all of these reasons, we believe the use of a 27-gauge system to treat challenging diabetic TRD cases makes a lot of sense.

Currently, a variety of 27-gauge instruments are commercially available for diabetic vitrectomy, including a high-speed cutter, a curved laser probe, a diathermy probe, membrane forceps, curved scissors, and a soft-tipped cannula. Of these, the most recently developed 27-gauge double-port cutter, with a second port in the internal guillotine blade of the cutter, has aspiration flow almost equal to or even a little bit better than that of a standard 25-gauge cutter (Figure 2, Video; eyetube.net/v.asp?f=eevim).³

RETROSPECTIVE REVIEW

In a pilot survey, we performed a retrospective chart review of a consecutive series of 40 patients who underwent primary 27-gauge vitrectomy for diabetic TRD or macula-threatening fibrovascular proliferation. The surgical results were compared with our previously reported case series treated with bevacizumab (Avastin, Genentech)-assisted 25- or 23-gauge vitrectomy.⁴

The study results are shown in Tables 1 and 2. Of the 80 study eyes, there was no significant difference in baseline characteristics between groups. However,

in the 27-gauge group, no eyes needed transition to larger size instruments, even in the most challenging cases, and no eyes needed suturing even with extensive peripheral vitreous shaving.

Overall anatomic success was comparable between groups. Operating time was a bit shorter for the 27-gauge group, possibly because use of additional instruments was less necessary for 27-gauge membrane dissection. We also had less need to perform bimanual manipulation with the 27-gauge device, suggesting that use of the 27-gauge cutter with one hand is sufficient to play several roles. This point has also been made by Berocca.⁴

Surprisingly, despite a much lower need for bevacizumab as a preoperative adjunct, there were few bleeding-related complications in the 27-gauge group. Intraocular pressure was stable from postoperative

“[I]t is important to ensure rigid wound construction to maintain intraocular pressure stability in order to prevent postoperative hypotony-related bleeding complications.”

TABLE 1. SURGICAL OUTCOMES OF SMALL-GAUGE DIABETIC VITRECTOMY: 27-GAUGE VS. 23- OR 25-GAUGE

	27-gauge Group	23- or 25-gauge Group	P Value
	n = 42	n = 38	
Preoperative bevacizumab injection [n, (%)]	6 (14)	38 (100)	
Operating time (min)	77 ± 37	85 ± 47	.35
Bimanual manipulation	15 (38)	23 (61)	.027
Instrumentation for FVM removal [n, (%)]			
Vitreoretinal forceps	18 (43)	23 (61)	.18
Membrane scissors and/or MPC	3 (7)	8 (21)	.041
Tamponade [n, (%)]			
Gas (air or long-acting gas)	18 (43)	18 (47)	.76
Silicone oil	0 (0)	1 (3)	.48
Self-sealing [n, (%)]	42 (100)	28 (74)	<.001
Initial reattachment [n, (%)]	40 (93)	36 (95)	1.00
Final reattachment [n, (%)]	42 (100)	38 (100)	1.00
Postoperative BCVA			
Mean (range)	0.34 (CF-1.0)	0.30 (HM-1.2)	.08
LogMAR ± SD	0.46 ± 0.51	0.51 ± 0.71	
Mean BCVA changes (logMAR ± SD)	-0.63 ± 0.66	-0.81 ± 1.16	.14

Abbreviations: BCVA, best corrected visual acuity; CF, counting fingers; FVM, fibrovascular membrane; HM, hand motion; MPC, membrane peeler-cutter; SD, standard deviation

TABLE 2. INTRAOPERATIVE AND POSTOPERATIVE COMPLICATIONS: 27-GAUGE VS. 23- OR 25-GAUGE

	27-gauge Group	23- or 25-gauge Group	P Value
	n = 42	n = 38	
Intraoperative complications			
Iatrogenic retinal breaks [n, (%)]	7 (17)	8 (21)	.83
Mean scores of intraoperative bleeding	2.2 ± 1.1	2.7 ± 0.9	.75
Postoperative complications [n, (%)]			
Hypotony	0 (0)	1 (3)	.48
Progressing or persistent NVG	1 (2.4)	3 (8)	.34
Progressive fibrovascular proliferation	1 (2.4)	2 (5)	.60
Persistent or recurrent VH	2 (5)	5 (13)	1.00
Recurrent retinal detachment	2 (5)	2 (5)	1.00
Vitreoretinal reoperation [n, (%)]	4 (10)	4 (11)	1.00

Abbreviations: NVG, neovascular glaucoma; VH, vitreous hemorrhage

No eyes needed transition to larger-size instruments even in the most challenging cases, and no eyes needed suturing even with extensive peripheral vitreous shaving. The overall anatomic success was comparable between the groups, but the operating time was a bit shorter for the 27-gauge group. Surprisingly, despite the lower chance of needing bevacizumab as a preoperative adjunct, there were few bleeding-related complications in the 27-gauge group.

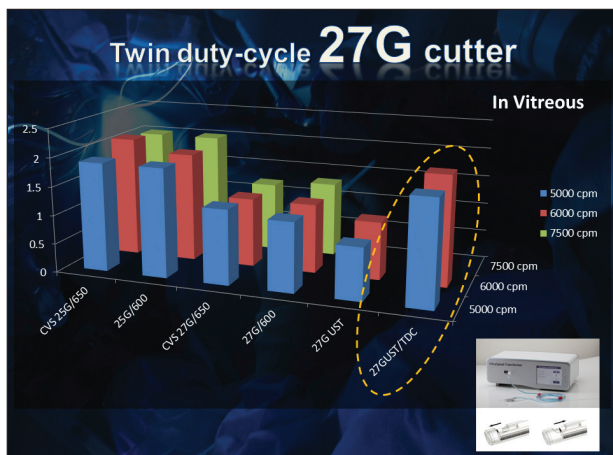


Figure 2. The cutting efficiency of the 27-gauge TDC cutter (yellow dashed line) in porcine vitreous at a variety of cutting rates is almost equal to or a little better than that of a conventional 25-gauge high-speed vitreous cutter.

day 1 throughout the 6-month follow-up period. As expected, visual acuity was significantly improved at 1 month after surgery. Changes in visual acuity at final examination were also comparable between the groups.

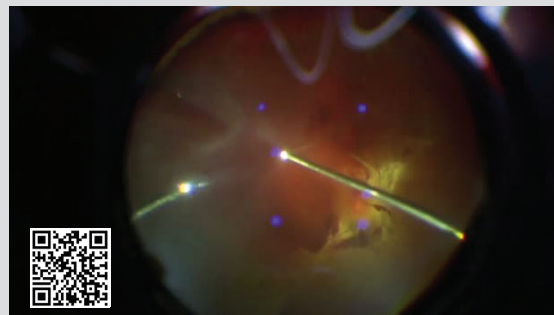
SNAPSHOT OF 27-GAUGE DIABETIC VITRECTOMY

Following is a description of a representative case of 27-gauge diabetic vitrectomy. After perpendicular insertion of a 27-gauge valved trocar cannula and a 29-gauge dual chandelier fiber, there is sufficient endoillumination to perform fibrovascular membrane dissection as usual, even with 27-gauge instruments. The 27-gauge cutter can be much more easily inserted into the tiny

“The latest developments in 27-gauge instruments, in conjunction with new vitrectomy machines, has made it possible to treat the full spectrum of vitreoretinal diseases ... with this ultrasmall-gauge technology.”

space between the membrane and the retina. With the use of wide-angle fundus viewing, it is also easy to carry out bimanual membrane dissection with the 27-gauge system. After extensive peripheral vitreous shaving with scleral indentation and panretinal laser photocoagulation with a curved endolaser probe, all cannulas and optical fibers are removed, and surgery is soon complete.

Video: Diabetic Vitrectomy With a 27-Gauge TDC Cutter



CONCLUSION

Although the study design of the pilot survey previously described had several limitations, the results help to confirm that the 27-gauge vitrectomy system offers at least comparable anatomic success in patients with diabetic TRD, with fewer intraoperative complications and favorable visual recovery compared with 23- and 25-gauge systems. The 27-gauge system not only simplified surgical procedures and shortened operating time, but it also significantly eliminated the wound-sealing concerns sometimes seen with current 23- and 25-gauge vitrectomy systems. The latest developments in 27-gauge instruments, in conjunction with new vitrectomy machines, has made it possible to treat the full spectrum of vitreoretinal diseases, including challenging diabetic TRDs, with this ultrasmall-gauge technology. ■

Yusuke Oshima, MD, is founder and director of the Oshima Eye Clinic in Takatsuki, a consultant and visiting surgeon at the Nishikasai Inoue Eye Hospital, a visiting lecturer of ophthalmology at Kyoto Prefectural University of Medicine, Kyoto, all in Japan; and an honorary director of the vitreoretinal division at the Tianjin Eye Hospital and visiting professor of ophthalmology at the Nankai University in Tianjin, China. He is a member of the Retina Today Editorial Board. Dr. Oshima states that he is a consultant for Synergetics. He may be reached at yusukeoshima@gmail.com.



- Oshima Y, Wakabayashi T, Sato T, et al. A 27-gauge instrument system for transconjunctival sutureless microincision vitrectomy surgery. *Ophthalmology*. 2010;117(1):93-102.
- Wakabayashi T, Oshima Y. Microincision vitrectomy surgery for diabetic retinopathy. *Retinal Physician*. October 2011.
- Osawa S, Oshima Y. Innovations in 27-gauge vitrectomy for sutureless microincision vitrectomy surgery. *Retina Today*. 2014;9(5):42-45.
- Oshima Y, Shima C, Wakabayashi T, et al. Microincision vitrectomy surgery and intravitreal bevacizumab as a surgical adjunct to treat diabetic traction retinal detachment. *Ophthalmology*. 2009;116(5): 927-938.
- Berrolcal M. A minimalist approach to surgery for diabetic retinal detachment. *Retina Today*. 2014;9(3):65-68.